

Assessment methods of vastus lateralis muscle architecture using panoramic ultrasound: a new approach, test-retest reliability and measurement error

Métodos de avaliação da arquitetura do músculo vasto lateral usando ultrassonografia panorâmica: nova abordagem, confiabilidade teste-reteste e erro da medida

André Luiz Conveniente Soares¹

 <https://orcid.org/0000-0002-1026-8639>

Fernando dos Santos Nogueira¹

 <https://orcid.org/0000-0001-7895-7484>

Paulo Sergio Chagas Gomes¹

 <https://orcid.org/0000-0003-0536-4164>

Abstract – Extended-field-of-view ultrasonography is a valid alternative to determine the dimensions of the skeletal striated muscle; however, some factors may influence the final measurement. The aim of this study was to determine the test-retest reliability and measurement error of vastus lateralis muscle architecture variables through internal anatomical landmarks and to compare three fixed determined points using extended-field-of-view ultrasonography. Twelve young (24 ± 6 years) adult university male students participated in the study. Images were obtained through extended-field-of-view ultrasonography of the vastus lateralis muscle. Measurements were made for muscle thickness (MT), fascicle length (FL), and fascicle penetration angle (FA) using a method that identifies internal anatomical landmarks. MT was also measured at predetermined distances of 2 cm proximal, 6 cm proximal, and 2 cm distal. One-way ANOVA with repeated measures did not identify any test-retest significant differences for all variables measured. Typical measurement error in centimeters (cm) or degrees ($^{\circ}$), coefficient of variation in percentage (%) and intraclass correlation coefficient were MT = 0.07 cm, 2.93%, 0.964; FL = 0.31 cm, 2.89%, 0.947; FA = 0.92 $^{\circ}$, 4.08%, 0.942; MT 2 cm proximal = 0.10 cm, 3.77%, 0.910; MT 6 cm proximal = 0.27 cm, 9.66%, 0.576; MT 2 cm distal = 0.35 cm, 19.76%, 0.564. MT, FL and FA showed high reliability and low measurement error. Internal anatomical landmarks proved to be more reliable and presented smaller measurement errors when compared to the predetermined distances method.

Key words: Anatomy; Hypertrophy; Lower extremity; Quadriceps muscle; Ultrasonography.

Resumo – A ultrassonografia panorâmica é uma alternativa válida para determinar as dimensões da musculatura estriada esquelética, entretanto alguns fatores podem influenciar a medida final. Objetivou-se determinar a confiabilidade e o erro da medida das variáveis da arquitetura do músculo vasto lateral através de marcações anatômicas internas, bem como comparar dois métodos de avaliação diferentes através da ultrassonografia panorâmica. Doze homens (idade: 24 ± 6 anos) participaram do estudo. As imagens foram obtidas através da ultrassonografia panorâmica do músculo vasto lateral. Foram realizadas as medidas da espessura muscular (EM), comprimento do fascículo (CF) e ângulo de penetração do fascículo (AP) através do método que identifica marcações anatômicas internas. A EM também foi medida através de distâncias predeterminadas de 2 cm proximal, 6 cm proximal e 2 cm distal. A ANOVA de uma via com medidas repetidas não identificou diferença significativa para todas as variáveis mensuradas, o erro típico de medida em centímetros (cm) ou graus ($^{\circ}$), o coeficiente de variação em percentual (%) e o coeficiente de correlação intraclass foram respectivamente: EM = 0,07 cm, 2,93%, 0,964; CF = 0,31 cm, 2,89%, 0,947; AP = 0,92 $^{\circ}$, 4,08%, 0,942; EM 2 cm proximal = 0,10 cm, 3,77%, 0,910; EM 6 cm proximal = 0,27 cm, 9,66%, 0,576; EM 2 cm distal = 0,35 cm, 19,76%, 0,564. EM, CF e AP apresentaram alta confiabilidade e baixo erro de medida. As marcações anatômicas internas demonstraram ser mais confiáveis e apresentam menores erros de medida quando comparados ao método de distâncias predeterminadas.

Palavras-chave: Anatomia; Extremidade inferior; Hipertrofia; Músculo quadríceps; Ultrassom.

¹ Universidade do Estado do Rio de Janeiro. Instituto de Educação Física e Desportos. Laboratory Crossbridges. Rio de Janeiro, RJ, Brasil

Received: August 13, 2020

Accepted: November 24, 2020

How to cite this article

Soares ALC, Nogueira FS, Gomes PSC. Assessment methods of vastus lateralis muscle architecture using panoramic ultrasound: a new approach, test-retest reliability and measurement error. Rev Bras Cineantropom Desempenho Hum 2021. 23:e76402. DOI: <http://doi.org/10.1590/1980-0037.2021v23e76402>

Copyright: This work is licensed under a [Creative Commons Attribution 4.0 International License](https://creativecommons.org/licenses/by/4.0/).



INTRODUCTION

Muscle architecture is commonly defined as the physical arrangement of muscle fibers at macroscopic level, which determines their mechanical function and can influence force generation¹. The most commonly monitored muscle architecture variables in exercise and sport science studies include muscle thickness (MT), fascicle length (FL) and fascicle pennation angle (FA)².

In vivo muscle architecture variables have been estimated by extrapolation of cadaveric specimens³. Bénard et al.⁴ used cadaveric data of the gastrocnemius muscle to demonstrate that conventional or static ultrasonography (US) can be used to identify MT, FL and FA. Kellis et al.⁵ found low mean typical errors for MT (0.09 to 0.14 cm), FL (0.92 to 1.71 cm) and FA (1.01 to 1.31°). Intraclass correlation coefficients between cadaveric and US methods ranged from 0.905 to 0.992 and from 0.774 to 0.972 for biceps femoris and semitendinosus muscles, respectively⁵, indicating that such measures can be reproduced with noninvasive brightness mode (B-Mode) static US technology.

MT measured using US has been validated against magnetic resonance imaging⁶, which is currently considered the gold standard procedure. US is definitively easier and cheaper alternative compared to more sophisticated imaging methods. In addition, US is radiation-free method compared to computerized axial tomography⁷.

US has been widely used to observe acute and chronic adaptations in muscle architecture variables in experimental studies, using resistance training exercises^{8,9}, electrical stimulation¹⁰, stretching exercises^{11,12}, among others, with special interest in the hypertrophic responses of specific muscle groups.

Static US is limited by the transducer size, usually 4 to 6 cm. Previous work by Weng et al.¹³ in late 1990s combined the convenience of modern real-time scanning (modern at that time) with the spatial advantages of static B-mode scanning, which allowed obtaining a panoramic or extended-field-of-view (EFOV) in real time in a much simpler setup. EFOV US consists of providing static images captured in real time through specific dedicated software¹⁴, allowing the quantification of muscle architecture variables without the need of trigonometric equations in order to predict them^{15,16}, avoiding prediction error, whose assumption is based on parallel aponeurosis.

The possibility of using noninvasive methods to determine the magnitude of muscle adaptations in intervention studies and the advantage of using less expensive instruments made it necessary to identify the typical error of this procedure, as well as to calculate its day-to-day reliability.

Blazevich et al.¹ and Ema et al.⁸ used internal anatomical landmarks in an attempt to standardize measurements made repeatedly on the same individual. The purpose was to increase the day-to-day reliability and decrease the measurement error in the determination of muscle architecture variables (MT, FL and FA) using static B-mode US. In both studies, FL

was determined using the prediction equation from Blazeovich et al.¹⁷

Noorkoiv et al.¹⁸ were the first authors to use EFOV US to measure vastus lateralis muscles and compare the results with measurements based on predictive equations from static US using 6 cm transducer.

Regardless of whether the final image result is a static B-Mode or EFOV, US measurements are potentially influenced by several factors: (a) identification and marking of external anatomical sites, based on clear description and capable of being repeated by the same or different evaluators; (b) ability to reproduce identification of the same site in successive measurements; (c) operator ability to manipulate the transducer; (d) identification of internal anatomical landmarks in the captured image in order to minimize errors in repeated measurements; (e) resolution of the apparatus being used; and (f) expertise in the quantification of muscle architecture variables using specific software.

The purpose of the present study was to propose an adaptation of the EFOV US method using the approach with internal anatomical landmarks used by Blazeovich et al.¹ and Ema et al.⁸ in their studies with static US. A detailed description is provided on the marking of both external and internal landmarks to make muscle architecture measurements (MT, FL and FA) more reliable and with less error. The secondary purpose was to compare two methods to determine MT, the first based on internal anatomical landmarks and the second using predetermined distances (in cm) identified in US imaging.

METHODS

Sample and Study Design

Twelve male adult university students (mean and standard deviation = 24 ± 6 years) were recruited to participate in the study. Each volunteer visited the laboratory on two occasions, with minimum of 24 hours and maximum of seven days between sessions. Subjects were requested not to perform any type of physical exercise in the 24 hours prior to testing sessions.

Before the beginning of the study, all subjects were requested to sign the informed consent form describing all of study procedures, which were based on norms of the Resolution of the National Health Council 466/2012. The study was approved by the Ethical Review Board of the “Pedro Ernesto” University Hospital (No. 2.531.389).

The inclusion criteria of participants were as follows: absence of any known musculoskeletal injury, age between 18 and 30 years and no use of nutritional ergogenic and/or pharmacological aids.

Determination of External Anatomic Landmarks

Each subject was placed on his back on a stretcher with right knee supported on a custom apparatus that generated a slight flexion to prevent its rotation. A guide rail made especially for this purpose was positioned in the lateral region of the thigh at 40% proximal between *trochanterion* and

tibiale laterale points, which determined the beginning of the image being scanned, with inclination of approximately 15° in relation to the sagittal plane between *iliocristale* and *patellare* points. The positioning of the guide rail can be seen in figures 1a, 1b and 1c. The *trochanterion* is the upper border of the femur greater trochanter. The *tibiale laterale* is the upper part of the lateral tibia epicondyle. The *iliocristale* is the upper border of the iliac crest. The *patellare* is the midpoint of the upper patella edge. All anatomical landmarks were defined based on descriptions recommended by the International Society for the Advancement of Kinanthropometry¹⁹.

Ultrasonographic Imaging Recordings

EFOV US images were acquired using ultrasonography device (GE Logiq E, GE Healthcare, USA) with dedicated software (GE LogicView, GE Healthcare, USA) equipped with 4-cm linear transducer (GE 9L-RS Probe, GE Healthcare, USA) operating at excitation frequency of 10 MHz and image depth of 6 cm. The linear transducer was placed at the beginning of the guide rail in its proximal edge (Figure 1c) and moved at constant speed throughout the rails toward the distal edge, providing image 13 cm long. Image renderization was automatically performed by the dedicated software.

Ultrasonographic images were obtained by experienced technician and stored in jpeg file format and later analyzed using free software. The same investigator collected and analyzed all images.

Measurement of Muscular Architecture Variables

Images were analyzed using open-source Java-based image processing free software (ImageJ, Ver. 1.50f, National Institutes of Health, USA) to quantify measurements.

The muscle architecture variables shown below were operationally defined as follows: (1) MT = longitudinal distance in cm between deep and superficial aponeurosis; (2) FL = distance in cm of the fascicle that extends from deep to superficial aponeurosis; (3) fascicle pennation angle (FA) = angulation in degrees formed between fascicle and deep aponeurosis.

The starting point for measuring variables was determined from the internal anatomical landmarks identified in all pairs of images for each subject. It is worth mentioning that these landmarks will be unique for each individual being scanned using US (Figure 1d).

In summary, the conversion of pixels to centimeters was completed in ImageJ software as follows: Analyze, Set Scale, Distance in pixels = 50; Known Distance = 1.00. The following line modes were used to determine architecture variables: (1) MT = quantified using the straight-line mode; (2) FL = quantified by the segmented line mode; and (3) FA = quantified with the angle tool mode.

To increase test-retest (day-to-day) reliability and decrease measurement error, variables were based on internal anatomical landmarks identified in the muscle image.

Internal anatomical landmarks in the medial part of the image were used to determine the starting point for measurement. This reference point was used because it provided good visualization of all variables to be measured (Figure 1d). For each pair of measurements, landmarks were marked to serve as reference points for subsequent measurements. Landmarks for both images (test-retest) of the same subject were the same but different for each subject assessed.

An alternative method of analysis, only for variable MT, was performed based on predetermined distances of 2 cm proximal, 6 cm proximal, and 2 cm distal of the vastus lateralis muscle along its longitudinal axis of the thigh (Figure 1e).

Statistical Analysis

Data normality was tested using Shapiro-Wilk statistics for small samples. One-way ANOVA with repeated measures was used to assess between-day differences for all muscle architecture variables. Intrarater test-retest reliability was tested using intraclass correlation coefficient (ICC) by means of two-way mixed-effects model, absolute agreement and single rater measurement. This procedure was based on McGraw and Wong²⁰ defined forms and on the model suggested by Shrout and Fleiss²¹.

The level of agreement between pairs of intrarater measurements was determined by Bland-Altman graphical analysis²², followed by Pearson's correlation coefficient between test differences and averages to identify the existence of heteroscedastic error.

The typical error of measurement (TEM) was considered to be the ratio between standard deviation (SD) of the difference between pairs of measurements and the square root of 2 ($TEM = SD / \sqrt{2}$), as suggested by Hopkins²³. The coefficient of variation (CV) was determined by dividing the standard deviation (SD) and the mean (X) between tests, and multiplying by one hundred ($CV = [SD / X] * 100$). Next, the mean CV was calculated from individual CVs to obtain the mean error percentage, as suggested by Atkinson and Nevill²⁴.

All statistical analyses were performed using commercially available statistical software (Statistical Package for the Social Sciences; SPSS Inc., Ver. 21, Chicago, IL, EUA). Bland-Altman graphic analysis was determined using another commercial software (SigmaPlot, Systat Software Inc, ver. 12, Chicago, IL, EUA). All statistical analyses were tested at 95% probability.

RESULTS

The results of the Shapiro-Wilk test did not identify any deviation from normality for any of variables under study.

One-way ANOVA with repeated measures did not identify any test-retest significant difference for all variables measured. Descriptive values for sample size, ANOVA results for between-day measurements, TEM,

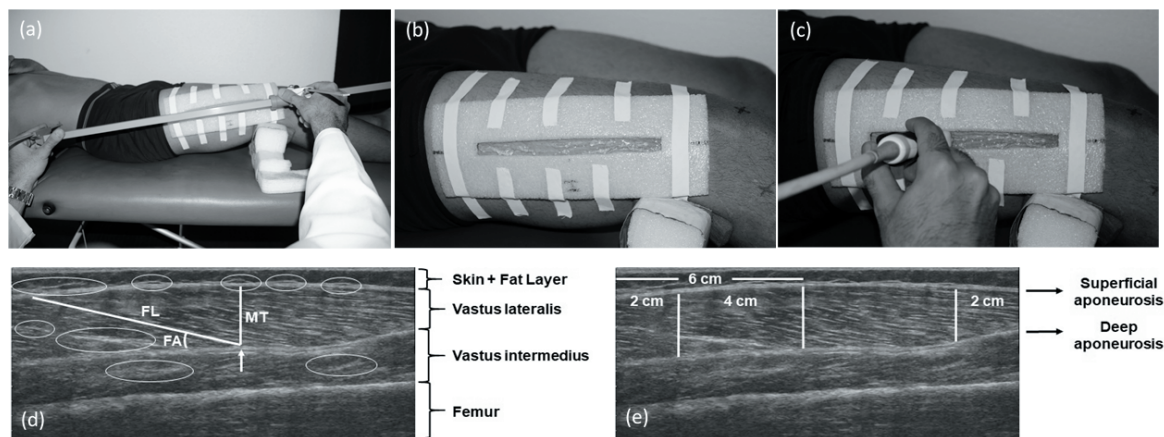


Figure 1. Determining the position of the guiding rail for transducer positioning (a, b, c); extended-field-of-view (EFOV) ultrasound images of the vastus lateralis muscle with internal anatomical landmarks identified (d) and with predetermined distances (e). MT = muscle thickness, FL = fascicle length, FA = fascicle pennation angle.

CV and ICC for all variables measured using the internal anatomical landmarks are presented in Table 1. Table 2 shows the MT analysis using predetermined distances.

The Bland-Altman graphic analysis demonstrating the degree of agreement between pairs of measures is shown in Figure 2, with mean of differ-

Table 1. Descriptive values (mean ± standard deviation) for total sample size (n=12), p values for one-way ANOVA with repeated measures, typical error of measurement (TEM) intra-rater, coefficient of variation (CV) and intraclass correlation coefficient (ICC) intra-rater reliability for selected vastus lateralis muscle architecture variables using internal anatomical landmarks.

Variables	Days	Mean ± SD	p value	TEM	CV	ICC (p)
MT	1	2.12 ± 0.35 cm	0.478	0.07 cm	2.93%	0.964 (0.000)
	2	2.10 ± 0.39 cm				
FL	1	8.35 ± 1.19 cm	0.492	0.31 cm	2.89%	0.947 (0.000)
	2	8.44 ± 1.42 cm				
FA	1	22.99 ± 4.47°	0.332	0.92°	4.08%	0.942 (0.000)
	2	22.08 ± 4.52°				

Note. MT = muscle thickness, FL = fascicle length, FA = fascicle pennation angle.

Table 2. Descriptive (mean ± standard deviation) values for total sample size (n=12), p values for one-way ANOVA with repeated measures, typical error of measurement (TEM) intra-rater, coefficient of variation (CV) and intraclass correlation coefficient (ICC) intra-rater reliability for selected vastus lateralis muscle thickness (MT) using predetermined distances (2 cm proximal, 6 cm proximal, 2 cm distal).

MT	Days	Mean ± SD	p value	TEM	CV	ICC (p)
MT by IAL	1	2.12 ± 0.35 cm	0.478	0.07 cm	2.93%	0.964 (0.000)
	2	2.10 ± 0.39 cm				
MT 2 cm proximal	1	2.20 ± 0.32 cm	0.309	0.10 cm	3.77%	0.910 (0.000)
	2	2.16 ± 0.32 cm				
MT 6 cm proximal	1	2.13 ± 0.40 cm	0.719	0.27 cm	9.66 %	0.576 (0.024)
	2	2.17 ± 0.39 cm				
MT 2 cm distal	1	1.65 ± 0.52 cm	0.298	0.35 cm	19.76 %	0.564 (0.021)
	2	1.81 ± 0.56 cm				

Note. MT = muscle thickness; IAL = internal anatomical landmarks.

ences between tests and retests and limits of agreement. None of variables had statistically significant Pearson correlation coefficient for differences between tests and average of the two tests, for each variable, indicating no heteroscedastic error. Pearson correlation coefficients (r) for MT, FL and FA of the reference method were $r = 0.39$ ($p = 0.21$), $r = 0.52$ ($p = 0.08$), and $r = 0.04$ ($p = 0.90$), respectively, while for the predetermined distance method, 2 cm proximal, 6 cm proximal, and 2 cm distal were -0.04 ($p = 0.91$), $r = -0.03$ ($p = 0.93$), $r = 0.08$ ($p = 0.81$), respectively.

Table 3. Intra and/or inter reliability measurement error of the vastus lateralis muscle architecture variables using static or panoramic ultrasound.

Source	n (M:W)	Age in years Mean ± DP	Condition	Scanning Method	Variable	Statistical Index
Current study	12 (12:0)	24 ± 6	Separate days	EFOV	MT	ICC = 0.964; CV = 2.93%; TEM = 0.07 cm ICC = 0.947; CV% = 2.89%; TEM = 0.31 cm ICC = 0.942; CV% = 4.08%; TEM = 0.92°
					FL	
					FA	
Noorkoiv et al. ¹⁴	10 (10:0)	20 ± 5	Same day	EFOV	FL	ICC = 0.95-1.00; CV = 1.0% ICC = 0.97; CV = 3.1%
			Separate days			
Ema et al. ⁸	10 (10:0)	22 ± 2	Separate days	Static	MT	ICC = 0.976-0.991; CV = 1.5-2.1% ICC = 0.838-0.966; CV = 1.0-1.7% ICC = 0.885-0.931; CV = 2.8-3.8%
					FL	
					FA	
Lima et al. ²⁵	14 (4:10)	22 ± 2	Same day	Static	MT	ICC = 0.95-0.97; CV = 3.12-3.84%; TEM = 0.10-0.18 cm ICC = 0.96; CV = 3.76%; TEM = 0.10 cm ICC = 0.80-0.87; CV = 3.98-6.33%; TEM = 0.31-0.47 cm ICC = 0.81; CV = 4.94%; TEM = 0.40 cm ICC = 0.90-0.92; CV = 3.68-5.43%; TEM = 0.10-0.15° ICC = 0.83; CV = 6.34%; TEM = 0.17°
			Separate days			
			Same day			
			Separate days			
			Same day			
Raj et al. ²⁶	21 (11:10)	68 ± 5	Separate days	Static	MT	ICC = 0.96 ICC = 0.80 ICC = 0.87
					FL	
					FA	

Note. MT = muscle thickness, FL = fascicle length, FA = fascicle pennation angle, EFOV = extended-field-of-view

DISCUSSION

The present study aimed to determine the test-retest (between days) reliability and measurement error of MT, FL, and FA of the vastus lateralis muscle using EFOV US based on the pre-identification of external and internal anatomical landmarks. The hypothesis was that the current approach would provide good test-retest reliability as well as low measurement error for muscle architecture variables. It was also hypothesized that MT measured using internal anatomical landmarks would provide lower measurement error and higher ICC compared with the predetermined distance technique.

The present study using EFOV found ICC and TEM values of 0.964 and 0.938, 0.07 cm and 0.92° for MT and FA, respectively. These values indicate higher reliability and smaller measurement errors than those found by Blazeovich et al.¹⁷. ICC and TEM values of FL in the current study were 0.947 and 0.31 cm, whereas in the aforementioned study, the values varied from 0.758 to 0.863 and from 1.0 to 1.9 cm, respectively. This difference was due to the limited assumptions of the predictive method used in static US. The prediction of FL using the equation of Blazeovich et al.¹⁷ assumes

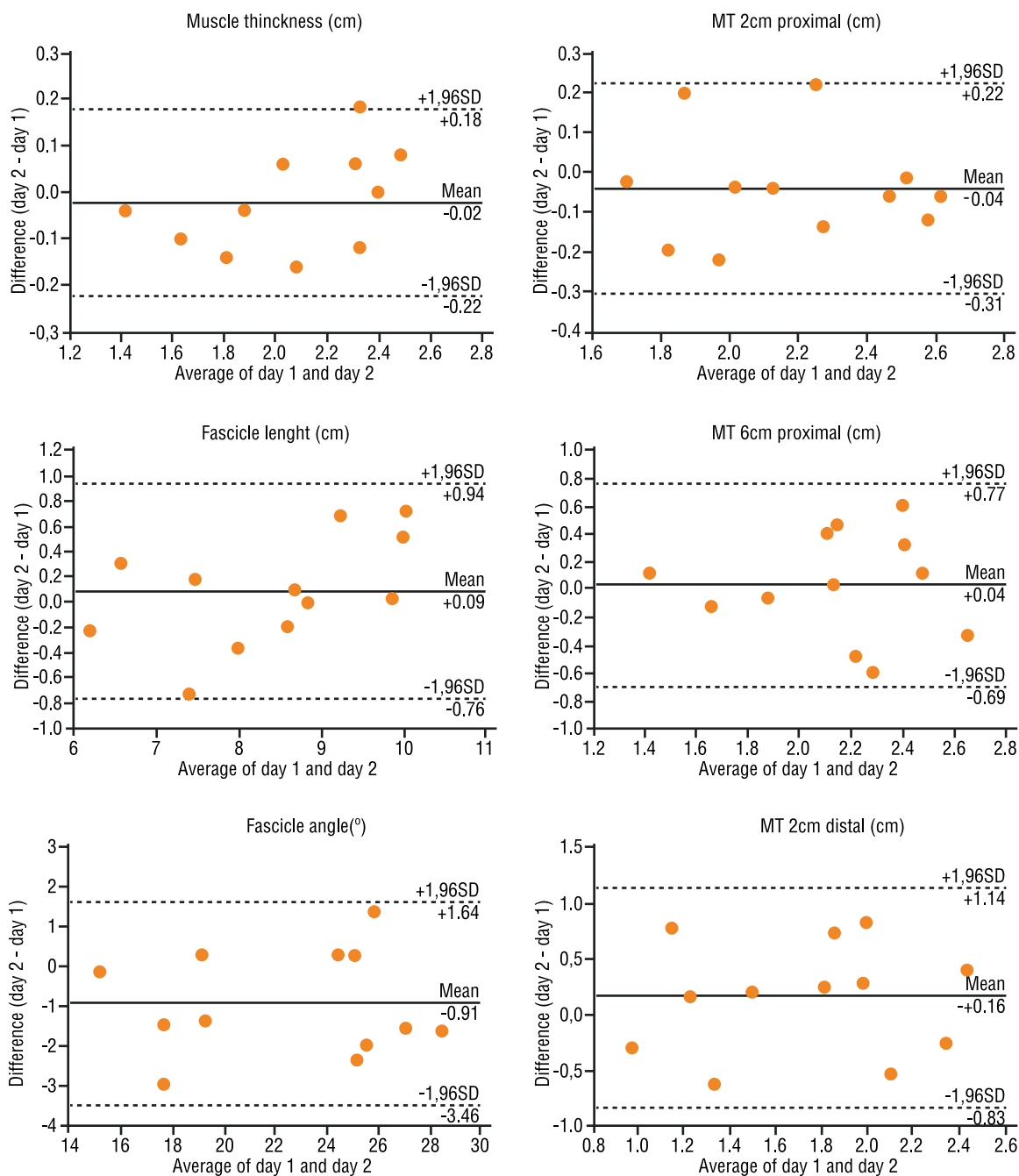


Figure 2. Bland-Altman graphic analysis of differences and means between days of muscle architecture variables. Graphs for measurements using internal anatomical landmarks are on the left. Muscle thickness (MT) with predetermined distances is on the right.

that the superficial and deep aponeurosis of the vastus lateralis muscle occurs parallel to the longitudinal axis of the muscle, which is not true. In addition, when using 4- or 6-cm transducers for static US, it is assumed that FL runs from its extension until it reaches an imaginary horizontal line between superficial and deep aponeurosis.

Ema et al.⁸, using static US, reported reliability and error values similar to those presented here (Table 3), using measures based on internal anatomical landmarks. In the study above, FL was predicted by linear

extrapolation when the entire fascicle was not visible.

Lima and Oliveira²⁵ determined MT, FL and FA of 14 young adults using static US and found ICCs ranging from 0.80 to 0.97 and CVs from 3.12 to 6.33%. Raj et al.²⁶ assessed the reliability of static US of 21 older adults and found ICCs of MT of 0.96, FL of 0.80 and FA of 0.87. The authors also used the equation of Blazevich et al.¹⁷ to determine the architecture measures of the vastus lateralis muscle. Studies reviewed are summarized in Table 3.

Noorkoiv et al.¹⁸, as well as the present study, used the EFOV US technique to determine FL of the vastus lateralis muscle. The ICC value varied between 0.95 and 0.97, while CV varied between 1.0% and 3.7%, confirming the high reliability and low error of the EFOV US method when compared to prediction equations.

The present study also compared the reliability and error of measurement of different methods used to determine MT (Table 2). The method of marking internal anatomical landmarks indicated higher ICC (0.964) and lower TEM (0.07 cm) and CV values (2.93%) compared to the method of predetermined distances, where ICC varied from 0.564 to 0.910, TEM from 0.10 to 0.35 cm and CV from 3.77 to 19.76%.

It became evident that measurements made using the method of predetermined distances of 6 cm proximal and 2 cm proximal and distal reliability values were lower and measurement errors were higher compared with internal anatomical landmarks, as shown in Table 2. Absolute values were not significantly different when comparing methods, probably due to the small sample size used in this introductory study.

The current results indicate that reliability increases when the evaluator uses internal anatomical landmarks as the reference point for measurements. This increases the probability and conviction that the possible changes observed in muscles are mainly due to treatment and not measurement error.

The Bland-Altman graphic analysis shown in Figure 3 demonstrates that errors have homoscedastic characteristics. Therefore, the magnitude of error tends to be similar regardless of variable magnitude.

Several studies have used static US to monitor adaptations of the vastus lateralis muscle architecture ranging from nine to twelve weeks of strength training in young adults performing extension-knee flexion. Ema et al.⁸ observed significant increases of 9.2% in MT and 10.8% in FA. Guilhem et al.²⁷ observed increases of 10.0% in MT and 11.0% in FA, while Wakahara et al.⁹ observed changes of 10.8% in FA. No study observed significant differences in FL.

Matta et al.²⁸ used different muscle (rectus femoris) and reported unusual extremely high increases in MT (47.4%) and FA (20.3%) resulting from 14 weeks of isotonic resistance training performed twice a week. Modifications such as those have not been previously reported.

The present study found measurement error for muscle architecture variables smaller than abovementioned hypertrophic adaptations, indicating that EFOV US is a method capable of monitoring smaller changes

generated by resistance training programs, for example.

Previous unpublished data from our laboratory have shown that when the muscle fascicle length was determined with prediction equations of Finni et al.¹⁶ and Kawakami et al.¹⁵, values show average overestimation of 12.4% and 15.8%, respectively, in relation to those observed with EFOV US. This observation reinforces the evidence, as previously discussed, that some of the basic assumptions of predictive equations are not true and can impair data interpretation.

Caresio et al.²⁹ and Salvi et al.³⁰ recently introduced software that automates the identification of superficial and deep muscle aponeurosis and detects MT and anatomical cross-section area of the muscle. These approaches seem to be promising in the area of ultrasound, since they allow for greater measurement consistency and less intra- and inter-rater errors.

CONCLUSIONS

All muscle architecture variables analyzed (MT, FL and FA) showed high reliability and low measurement error, indicating that the EFOV US method described here can be used to monitor muscular architecture modifications derived from interventions.

Another aspect to be considered is that the method of marking internal anatomical landmarks, as measurement reference, proved to be more reliable and showed less error when compared to that using predetermined distances.

It is necessary to determine the reliability and measurement error of other muscle groups so that the EFOV US method, as described, can be consolidated to monitor adaptations in future studies.

COMPLIANCE WITH ETHICAL STANDARDS

Funding

Soares ALC: supported by scholarship from PIBIC/UERJ. Nogueira FN: supported by scholarship from FAPERJ. Gomes PSC: supported in part by Productivity Research Grant from CNPq and PORCIÊNCIA grant from UERJ.

Ethical approval

Ethical approval was obtained from the local Human Research Ethics Committee – “Pedro Ernesto” University Hospital (HUPE), State University of Rio de Janeiro (UERJ), Protocol number: 2.531.389. The research was written in accordance with standards set by the Declaration of Helsinki.

Conflict of interest statement

The authors have no conflict of interests to declare.

Author Contributions

Conceived and designed the experiments: ALCS, FSN and PSCG. Performed the experiments: ALCS and FN. Analyzed data: ALCS and PSCG. Contributed with reagents/materials/analysis tools: PSCG. Wrote the paper: ALCS, FSN and PSCG. All authors read and approved the final version of the manuscript.

REFERENCES

1. Blazevich AJ, Cannavan D, Coleman DR, Horne S. Influence of concentric and eccentric resistance training on architectural adaptation in human quadriceps muscles. *J Appl Physiol* 2007;103(5):1565-75.
2. Franchi M V., Raiteri BJ, Longo S, Sinha S, Narici M V., Csapo R. Muscle architecture assessment: strengths, shortcomings and new frontiers of in vivo imaging techniques. *Ultrasound Med Biol* 2018;44(12):2492-504.
3. Friederich JA, Brand RA. Muscle fiber architecture in the human lower limb. *J Biomech* 1990;23(1):91-5.
4. Bénard MR, Becher JG, Harlaar J, Huijing PA, Jaspers RT. Anatomical information is needed in ultrasound imaging of muscle to avoid potentially substantial errors in measurement of muscle geometry. *Muscle Nerve* 2009;39(5):652-65.
5. Kellis E, Galanis N, Natsis K, Kapetanios G. Validity of architectural properties of the hamstring muscles: correlation of ultrasound findings with cadaveric dissection. *J Biomech* 2009;42(15):2549-54.
6. Dupont AC, Sauerbrei EE, Fenton P V., Shragge PC, Loeb GE, Richmond FJR. Real-time sonography to estimate muscle thickness: comparison with MRI and CT. *J Clin Ultrasound* 2001;29(4):230-6.
7. Sipilä S, Suominen H. Muscle ultrasonography and computed tomography in elderly trained and untrained women. *Muscle Nerve* 1993;16(3):294-300.
8. Ema R, Wakahara T, Miyamoto N, Kanehisa H, Kawakami Y. Inhomogeneous architectural changes of the quadriceps femoris induced by resistance training. *Eur J Appl Physiol* 2013;113(11):2691-703.
9. Wakahara T, Ema R, Miyamoto N, Kawakami Y. Increase in vastus lateralis aponeurosis width induced by resistance training: implications for a hypertrophic model of pennate muscle. *Eur J Appl Physiol* 2015;115(2):309-16.
10. Devrimsel G, Metin Y, Beyazal MS. Short-term effects of neuromuscular electrical stimulation and ultrasound therapies on muscle architecture and functional capacity in knee osteoarthritis: a randomized study. *Clin Rehabil* 2019;33(3):418-27.
11. Blazevich AJ, Cannavan D, Waugh CM, Miller SC, Thorlund JB, Aagaard P, et al. Range of motion, neuromechanical, and architectural adaptations to plantar flexor stretch training in humans. *J Appl Physiol* 2014;117(5):452-62.
12. César EP, Teixeira LO, de Souza DVBC, Gomes PSC. Acute effects of passive static stretching on the vastus lateralis muscle architecture of healthy young men. *Rev Bras Cineantropom Desempenho Hum* 2017;19(5):585-95.
13. Weng L, Tirumalai AP, Lowery CM, Nock LF, Gustafson DE, von Behren PL KJ. US extended-field-of-view imaging technology. *Radiology* 1997;203(3):877-80.
14. Noorkoiv M, Nosaka K, Blazevich AJ. Assessment of quadriceps muscle cross-sectional area by ultrasound extended-field-of-view imaging. *Eur J Appl Physiol* 2010;109(4):631-9.
15. Kawakami Y, Abe T, Kuno SY, Fukunaga T. Training-induced changes in muscle architecture and specific tension. *Eur J Appl Physiol Occup Physiol* 1995;72(1-2):37-43.
16. Finni T, Ikegawa S, Lepola V, Komi P V. Comparison of force-velocity relationships of vastus lateralis muscle in isokinetic and in stretch-shortening cycle exercises. *Acta Physiol Scand* 2003;177(4):483-91.

17. Blazeovich AJ, Gill ND, Zhou S. Intra- and intermuscular variation in human quadriceps femoris architecture assessed in vivo. *J Anat* 2006;209(3):289-310.
18. Noorkoiv M, Stavnsbo A, Aagaard P, Blazeovich AJ. In vivo assessment of muscle fascicle length by extended field-of-view ultrasonography. *J Appl Physiol* 2010;109(6):1974-9.
19. Stewart AD, Marfell-Jones M, Olds T, De Ridder H. International Standards for Anthropometric Assessment. Lower Hutt, New Zealand. 2011.
20. McGraw KO, Wong SP. Forming inferences about some intraclass correlation coefficients. *Psychol Methods* 1996;1(1):30-46.
21. Shrout PE, Fleiss JL. Intraclass correlations: uses in assessing rater reliability. *Psychol Bull* 1979;86(2):420-8.
22. Bland JM, Altman DG. Statistical methods for assessing agreement between two methods of clinical measurement. *Lancet* 1986;327(8476):307-10.
23. Hopkins WG. Measures of reliability in sports medicine and science. *Sports Med* 2000;30(1):1-15.
24. Atkinson G, Nevill AM. Statistical methods for assessing measurement error (reliability) in variables relevant to sports medicine. *Sports Med* 1998;26(4):217-38.
25. Lima KMM, Oliveira LF. Reliability of the measurements of architecture of the Vastus Lateralis muscle by ultrasonography. *Motriz: J Phys Ed* 2015;19(1):217-23.
26. Raj IS, Bird SR, Shield AJ. Reliability of ultrasonographic measurement of the architecture of the vastus lateralis and gastrocnemius medialis muscles in older adults. *Clin Physiol Funct Imaging* 2012;32(1): 65-70.
27. Guilhem G, Cornu C, Maffiuletti NA, Guével A. Neuromuscular adaptations to isoload versus isokinetic eccentric resistance training. *Med Sci Sports Exerc* 2013;45(2):326-35.
28. Matta TT, Nascimento FXMB, Fernandes IA, Oliveira LF. Heterogeneity of rectus femoris muscle architectural adaptations after two different 14-week resistance training programmes. *Clin Physiol Funct Imaging* 2015;35(3):210-5.
29. Caresio C, Salvi M, Molinari F, Meiburger KM, Minetto MA. Fully automated muscle ultrasound analysis (MUSA): robust and accurate muscle thickness measurement. *Ultrasound Med Biol* 2017;43(1):195-205.
30. Salvi M, Caresio C, Meiburger KM, Santi B, Molinari F, Minetto MA. Transverse muscle ultrasound analysis (TRAMA): robust and accurate segmentation of muscle cross-sectional area. *Ultrasound Med Biol* 2019;45(3):672-83.

Corresponding author

Paulo Sergio Chagas Gomes, Ph.D.
Universidade do Estado do Rio de Janeiro,
Instituto de Educação Física e Desportos, Laboratory Crossbridges,
Av. São Francisco Xavier, n. 524, Bloco F, 8o andar, Sala 8104,
Maracanã, Rio de Janeiro - RJ, 20550-900. Brasil.
E-mail: paulo.gomes@uerj.br